

## Pulmonary Fungal Ball of *Pseudallescheria boydii* Identified by LSU rDNA D2 Region Sequencing

Miyoung Kim, Mi-Hee Ahn, Ji Sang Kang, Hyun Lee, Sei-Ick Joo, Sung Sup Park, Eui-Chong Kim

Department of Laboratory Medicine, Seoul National University Hospital, Seoul, Korea

We report a case of pulmonary fungal ball of *Pseudallescheria boydii* (*Scedosporium apiospermum*, the anamorph) and the result of LSU rDNA D2 region sequencing of the clinical isolate. An immunocompetent 58-year-old female suffered 2-year history of hemoptysis. Her symptom persisted despite the administration of oral itraconazole, even though the clinical, radiological, and histological findings suggested *Aspergilloma*. In the fungal culture, the typical morphology of *S. apiospermum* was observed. Even though the sequencing using LSU rDNA D2 region

identified the organism as *Pseudallescheria ellipsoidea*, one of the *P. boydii* complex, the further investigation of ours suggested that the species in *P. boydii* complex could not be differentiated from each other by the sequencing of LSU rDNA D2 region. (Korean J Clin Microbiol 2009;12:87-91)

**Key Words:** *Scedosporium apiospermum*, *Pseudallescheria boydii*, *Pseudallescheria ellipsoidea*

### INTRODUCTION

*Scedosporium apiospermum* is the asexual anamorph of *Pseudallescheria boydii*[1-3]. It is an ubiquitously present saprophytic fungi, isolated from natural substances, including soil, stream water, poultry, and cattle, with unknown mode of transmission[3-8]. As an emerging pathogen, it causes a wide range of diseases, from subcutaneous mycetoma in immunocompetent host to disseminated sepsis in organ transplanted patients[3-5,9,10]. In patients with cavitating or chronic suppurative lung diseases such as tuberculosis, bronchiectasis, or cystic fibrosis, it may develop localized invasive lung infection which is clinically similar to that caused by *Aspergillus* [4,5,9]. However, the treatment of *S. apiospermum* (*P. boydii*) requires voriconazole or surgery sometimes, not amphotericin B[4,5,9]. Recently, some researchers suggest *P. boydii* is a species complex including *Pseudallescheria ellipsoidea* distinguished by different pathological behavior, antifungal susceptibility, and rDNA sequence[7,8,11]. We introduce our experience with the pulmonary mycetoma of *S. apiospermum* and the result of LSU rDNA

D2 region sequencing.

### CASE REPORT

A 58-year-old woman was admitted to Seoul National University Hospital, Seoul, Korea, complaining of a 2-year history of hemoptysis. Based on fungal hyphae in lung fine needle aspiration biopsy, she had been diagnosed to have fungal ball in her right upper lobe of the lung at her initial presentation at another hospital. She had been treated with intermittent antibiotics for one and a half years and oral itraconazole for the past 6 months. Despite the treatment, her blood tinged sputum persisted. She did not complain of any other symptoms. Physical examination revealed no specific findings. She had no history of diabetes, hypertension, trauma, tuberculosis, or medication including steroid treatment. Results of complete blood cell count were as follows: white blood cell count, 9,000/uL; hemoglobin, 14.1 g/dL; and platelet, 316,000/uL. There was no evidence of tuberculosis infection in acid fast stain and culture of her sputum. Chest radiographs showed oval nodule in right upper lobe. Computed tomography scan disclosed oval low attenuating lesion sized 2.9 cm in right upper lobe suggesting fungal ball rather than tumor (Fig. 1), and accompanying bronchiectasis in right upper lobe and left lower lobe (Fig. 2). Bronchoscopy showed no endobronchial lesion. The patient went under the lobectomy of right

Received 7 January, 2009, Revised 7 April, 2009

Accepted 15 May, 2009

Correspondence: Eui-Chong Kim, Department of Laboratory Medicine, Seoul National University Hospital, 101, Daehangno, Jongno-gu, Seoul 110-744, Korea. (Tel) 82-2-2072-3500, (Fax) 82-2-747-0359, (E-mail) euichong@snu.ac.kr

upper lobe. In the tissue specimen, a 2.7×2×2 cm sized cavity was observed. The cavity was filled with a necrotizing material of dark brown color and surrounded by multiple cysts (the size of the largest cyst: 1.5×1×1 cm). Histological examination with Gomori methenamine silver (GMS) stain and periodic acid-Schiff (PAS) stain demonstrated numerous branching, septated hyphae (Fig. 3). Based on these findings, the histopathological diagnosis included chronic active inflammation, bronchiectasis accompanied by fibrosis and calcification, reactive hyperplasia in four peribronchial lymph nodes, and fungus ball, morphologically *Aspergilloma*. The surgical specimen was cultured in Sabouraud dextrose agar (SDA, Hanil KOMED, Seoul, Korea) and Sabouraud dextrose agar with chloramphenicol (SC, Hanil KOMED, Seoul, Korea) at 30°C. On the 8th culture day, the isolate started to grow. The surface of the both agars grew cotton like white mycelium, which later turned brown (Fig. 4). The reverse were white at first then became smoky brown. We performed slide culture of the isolate for 4 days and lacto-phenol cotton blue stain for microscopic examination. The microscopic examination showed septated hyphae with simple long or short conidiophores with conidia singly or in clusters. The conidia were unicellular and oval, and had the larger end toward the apex, and cut off at base (Fig. 5). Pure culture was performed on Mycosel agar (Becton Dickinson, Sparks, MD, USA) to confirm the uninhibited growth in cycloheximide. The isolate grew on the 10th day of the pure culture. The organism was identified as *S. apiospermum* based on the microscopic features and uninhibited growth in agar with cycloheximide. Sexual stage was not observed. No other microorganisms were isolated from the specimen. Sequencing was followed to confirm the microbiological diagnosis. MicroSeq ID Analysis D2 LSU rDNA Fungal Sequencing Kit (Applied Biosystems, CA, USA), ABI PRISM 3130 Genetic Analyser (Applied Biosystems, CA, USA), and MicroSeq Analysis Software Version 2.0 (Applied

Biosystems, CA, USA) were used. The sequencing of LSU rDNA, D2 region identified the isolate as *P. ellipsoidea* with 100% match. Her 5-month postoperative course was rather complicated due to postoperative hematoma followed by vancomycin-intermediate *Staphylococcus aureus* infection, but she was recovered completely and discharged.

## DISCUSSION

Pulmonary fungal ball of *S. apiospermum* (or *P. boydii*, the teleomorph) requires fungal culture followed by histological examination or *Aspergillus* antibody test for the differential diagnosis from *Aspergilloma*[3,9,10,12-14]. As noted in our case, radiographic or histopathologic examination cannot differentiate *Scedosporium* from *Aspergillus*, and the diagnostic confusion may complicate the management of *Scedosporium* infection[3,12]. It also suggests that the prevalence of *S. apiospermum* (or *P. boydii*) infection, especially the mycetomatous form could have been underestimated[12].

Chemotherapeutic agents used for the treatment of disseminated infection of *S. apiospermum* are different from those for the *Aspergillus* infection[4,5,9]. Voriconazole is the drug of choice so far. Posaconazole and ravuconazole are effective as well, while echinocandins exhibit some activity in vitro[8,9]. For the cases of a localized disease, surgical resection and/or adjuvant chemotherapy has been recommended[3,14]. Our patient underwent surgical resection of the fungal ball without additional chemotherapy which was sufficient for the management of the *S. apiospermum* mycetoma.

Unlike other pathogenic fungi, it is well known that *Scedosporium* has ability to develop sexual on routine culture me-

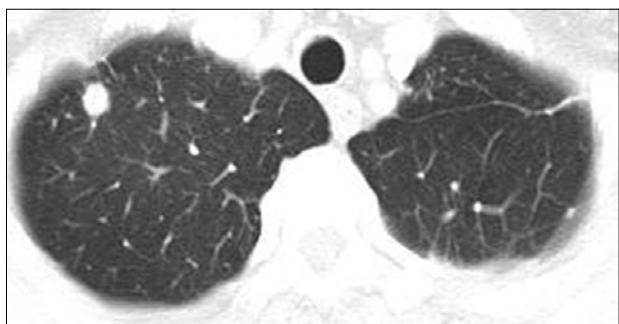

Fig. 1. Chest CT shows a round opacity in the right upper lobe.

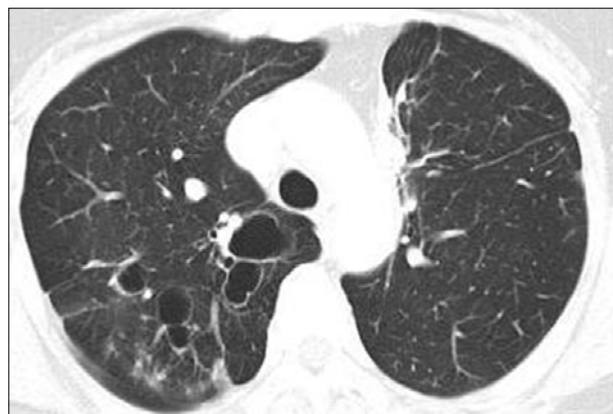
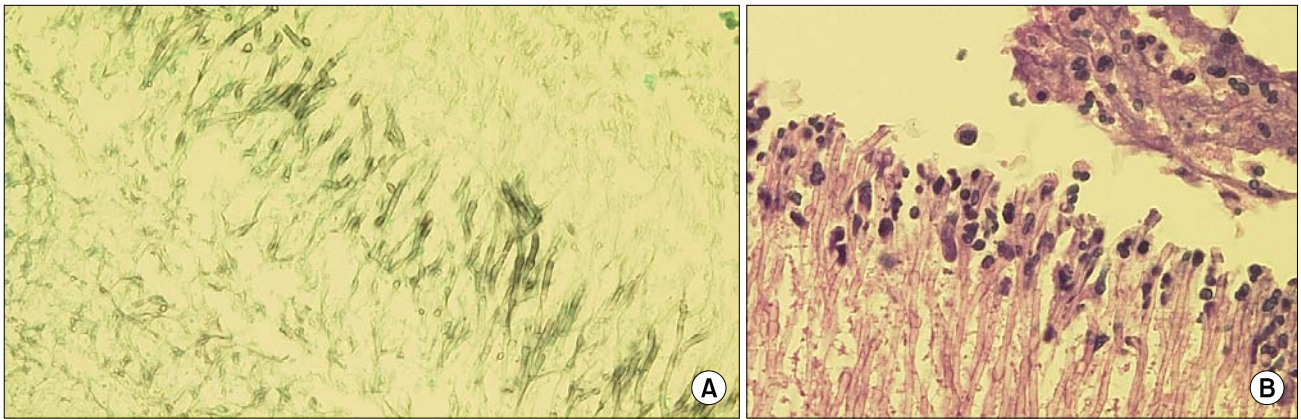
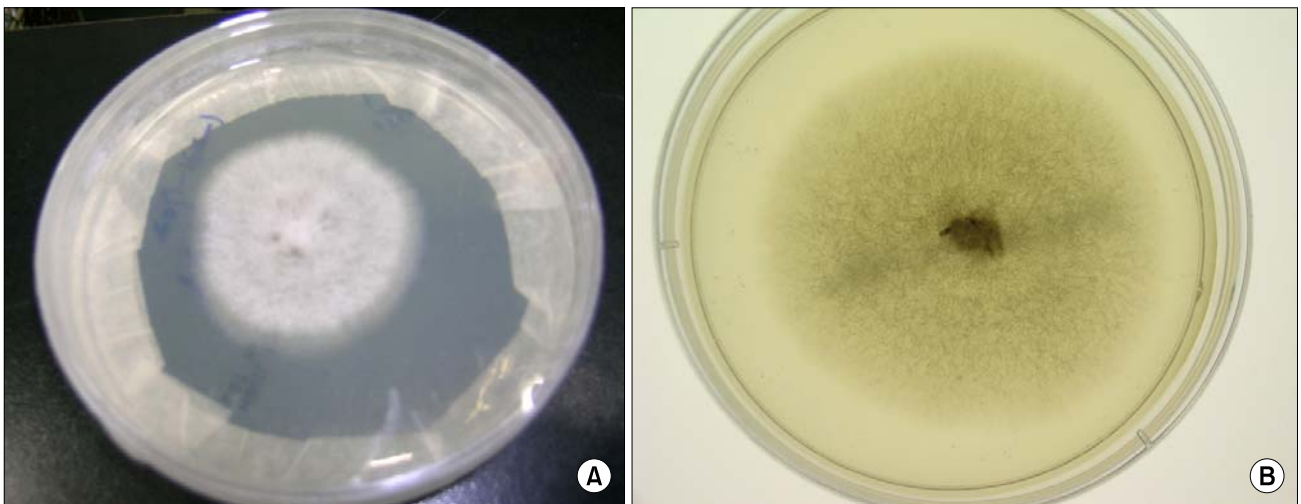


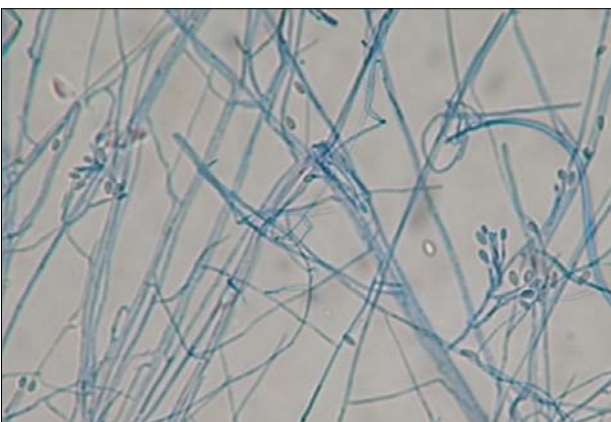
Fig. 2. Chest CT shows bronchiectasis in the right upper lobe.



**Fig. 3.** Histological examinations of numerous branching, septated hyphae stained with (A) Gomori methenamine silver (GMS) and (B) periodic Acid-Schiff (PAS) (×400).



**Fig. 4.** The white to brown colored cottony colonies growing on Sabouraud's dextrose agar (A) front and (B) reverse.



**Fig. 5.** Microscopic examinations of a colony on the slide culture stained with lacto-phenol cotton blue, showing septated hyphae with simple conidiophores with conidia (×400).

dia[7]. Only the anamorph was observed, and we performed genotyping for further verification. The fungal isolate was identified as *Pseudallescheria ellipsoidea*, not *S. scedosporium* nor *P. boydii*, using MicroSeq ID Analysis D2 LSU rDNA Fungal Sequencing Kit (Applied Biosystems, CA, USA).

Recently, it has been proposed that *P. boydii*, the teleomorph, is not a single species, but a species complex which consists of at least six different species (*P. boydii*, *P. angusta*, *P. ellipsoidea*, *P. fusioidea*, *P. minutispora*, and *S. aurantiacum*)[7,8,11]. These species are believed to be different not only in partial sequence of  $\beta$ -tubulin genes, calmodulin genes, and the internal transcribed spacer (ITS) region of the rDNA, but also in respect to growth rate, morphology, pathogenicity, and antifungal susceptibility[7,8]. However, some researchers argue that *P. angusta*, *P. ellipsoidea*, and *P. fusioidea* are the synonyms of *P. boydii*

since those differences are not significant enough in terms of sequence and clinical behavior[8,15].

In ABI fungal library 2.0, *P. ellipsoidea* is the only species present. None of other suggested species in *P. boydii* complex or *P. boydii* itself does not exist in the library. We compared the homology of commonly used part of LSU D2 region of *P. boydii* and *P. ellipsoidea* from NCBI using EMBL-EBI (European Bioinformatics Institute) clustalW2 program (<http://www.ebi.ac.uk/Tools/clustalw2>). Only 6 nucleotides out of 379 base pairs showed difference between the two species, suggesting that *P. ellipsoidea* could not be easily distinguished from *P. boydii* by sequencing the commonly used part of LSU D2 region. The sequence of our isolates (436 bp) using the MicroSeq kit was also compared with the sequence of *P. boydii* and *P. ellipsoidea* using the same method, and only 8 and 6 nucleotide difference were observed, respectively.

Based on these findings, we infer that the result from MicroSeq Analysis Software Version 2.0 simply means that our isolate could be any one of the suggested species in *P. boydii* complex. Another possible explanation is that those suggested species are synonyms of *P. boydii*, and they do not differ significantly in respect to gene sequence. Further study with  $\beta$ -tubulin genes, calmodulin genes, and the ITS region sequencing might be helpful to resolve this issue.

We presented a case of localized lung *Scedosporiosis* in an immunocompetent host with underlying bronchiectasis. The symptom of hemoptysis had not been controlled by the administration of conventional antifungal agent, even though the clinical, radiological, and histological findings had suggested *Aspergilloma*. In fungal culture, the typical morphology of *S. apiospermum* was observed. Even though the sequencing of LSU rDNA D2 region identified the organism as *P. ellipsoidea*, the further investigation of ours implies that the suggested species in *P. boydii* complex could not be differentiated from each other through the sequencing of LSU rDNA D2 region. Further study with sequencing of other region might resolve this issue, even though it is still possible that those suggested species are not significantly different from each other in genotypic or clinical aspects.

## REFERENCES

1. Katragkou A, Dotis J, Kotsiou M, Tamiolaki M, Roilides E. *Scedosporium apiospermum* infection after near-drowning. *Mycoses* 2007;50:412-21.
2. Horré R, Jovanić B, Marklein G, Schumacher G, Friedrichs N, Neuhaus T, et al. Fatal pulmonary scedosporiosis. *Mycoses* 2003; 46:418-21.
3. Raj R and Frost AE. *Scedosporium apiospermum* fungemia in a lung transplant recipient. *Chest* 2002;121:1714-6.
4. Murayama T, Amitani R, Tsuyuguchi K, Watanabe I, Kimoto T, Suzuki K, et al. Polypoid bronchial lesions due to *Scedosporium apiospermum* in a patient with *Mycobacterium avium* complex pulmonary disease. *Eur Respir J* 1998;12:745-7.
5. Williamson EC, Speers D, Arthur IH, Harnett G, Ryan G, Inglis TJ. Molecular epidemiology of *Scedosporium apiospermum* infection determined by PCR amplification of ribosomal intergenic spacer sequences in patients with chronic lung disease. *J Clin Microbiol* 2001;39:47-50.
6. Larone DH. *Medically Important Fungi*. 4th ed. Washington D.C; ASM Press, 2002:196-197.
7. Gilgado F, Cano J, Gené J, Guarro J. Molecular phylogeny of the *Pseudallescheria boydii* species complex: proposal of two new species. *J Clin Microbiol* 2005;43:4930-42.
8. Cortez KJ, Roilides E, Quiroz-Telles F, Meletiadiis J, Antachopoulos C, Knudsen T, et al. Infections caused by *Scedosporium* spp. *Clin Microbiol Rev* 2008;21:157-97.
9. Abgrall S, Pizzocolo C, Bouges-Michel C, Martinod E, Martin A, Brauner M, et al. *Scedosporium apiospermum* lung infection with fatal subsequent postoperative outcome in an immunocompetent host. *Clin Infect Dis* 2007;45:524-5.
10. Severo LC, Oliveira Fde M, Irion K. Respiratory tract intracavitary fungal ball due to *Scedosporium apiospermum*: report of four cases. *Rev Inst Med Trop Sao Paulo* 2004;46:43-6.
11. Gilgado F, Serena C, Cano J, Gené J, Guarro J. Antifungal susceptibilities of the species of the *Pseudallescheria boydii* complex. *Antimicrob Agents Chemother* 2006;50:4211-3.
12. Koga T, Kitajima T, Tanaka R, Hirokawa M, Ichiki M, Rikimaru T, et al. Chronic pulmonary scedosporiosis simulating aspergillosis. *Respirology* 2005;10:682-4.
13. Kang CS, Han KJ, Lee KY, Shim SI, Kim YS. Pulmonary pseudallescheriasis: a case report and histopathologic comparison with pulmonary aspergillosis. *Korean J Pathol* 1998;32:147-9.
14. Al Refai M, Duhamel C, Le Rochais JP, Icard P. Lung scedosporiosis: a differential diagnosis of aspergillosis. *Eur J Cardiothorac Surg* 2002;21:938-9.
15. Rainer J, de Hoog GS, Wedde M, Gräser Y, Gilges S. Molecular variability of *Pseudallescheria boydii*, a neurotropic opportunist. *J Clin Microbiol* 2000;38:3267-73.

=국문초록=

## LSU D2부위 염기서열로 확인한 *Pseudallescheria boydii*에 의한 폐 진균종 증례

서울대학교병원 진단검사의학과

김미영, 안미희, 강지상, 이 현, 주세익, 박성섭, 김의종

본 증례는 *Pseudallescheria boydii* (*Scedosporium apiospermum*, the anamorph)에 의한 폐진균종과 이를 LSU rDNA D2 부위를 sequencing한 결과에 관한 보고이다. 면역 기능 저하의 증거가 없는 58세 여자 환자가 2년간의 객혈을 주소로 내원하였다. 임상적, 방사선학적, 조직학적 소견에 근거하여 Aspergilloma로 진단받고 경구 itraconazole을 투여하였으나, 호전되지 않았다. 진균 배양에서 전형적인 *S. apiospermum*의 형태가 관찰되었다. LSU rDNA D2 부위의 sequencing을 통해 *P. boydii* complex의 한 종류인 *Pseudallescheria ellipsoidea*로 동정되었다. 그러나, 우리의 추가 연구 결과는 LSU rDNA D2 region의 sequencing만으로는 일부 연구자들이 주장하는 *P. boydii* complex 내의 세부 균종 간의 구별은 불가능함을 시사하였다. [대한임상미생물학회지 2009;12:87-91]

교신저자 : 김의종, 110-744, 서울시 종로구 대학로 101번지  
서울대학교병원 진단검사의학과  
Tel: 02-2072-3500, Fax: 02-747-0359  
E-mail: euichong@snu.ac.kr