

Two Cases of Cryptococcuria Developed as Isolated Cryptococcuria and Disseminated Cryptococcosis

Mi Hyun Bae¹, Seung Namgoong¹, Dongheui An¹, Mi-Na Kim¹, Sung-Han Kim², Ki-Ho Park², Sung-Gyu Lee³

¹Department of Laboratory Medicine, ²Division of Infectious Diseases, and ³Department of Surgery, University of Ulsan College of Medicine, Asan Medical Center, Seoul, Korea

Cryptococcus is an opportunistic pathogen that mainly affects immunocompromised hosts and, less frequently, immunocompetent hosts. It causes serious morbidity and mortality due to systemic infections such as meningoencephalitis and pulmonary infection. Urinary involvement of *Cryptococcus* is sometimes reported among cases of disseminated cryptococcosis in AIDS patients, but no such reports have been published in Korea. We report two cases of cryptococcuria that developed in a 71-year old female with diabetes and liver cirrhosis and in a 50-year old male who received a liver transplant due to HBV-associated hepatic failure. The female patient had received prednisolone for 12 days before we detected *C. neoformans* in urine culture. Even though no antifungal therapy was indicated for cryptococcuria, following

urine culture became negative, but still positive for cryptococcal antigen on hospital day 25. Her blood, CSF culture, and antigen tests were negative, and therefore she was diagnosed with isolated cryptococcuria. The male patient had received prednisolone and tacrolimus for 10 days before sputum and urine cultures became positive for *C. neoformans*. He had ill defined nodules and pleural effusion in both lungs on chest CT. His cryptococcuria was sustained for over 2 months, despite receiving amphotericin B treatment. His cryptococcuria seemed to be a symptom of disseminated cryptococcosis. (Korean J Clin Microbiol 2011;14:148-152)

Key Words: *Cryptococcus neoformans*, Cryptococcuria, Urine, Culture

INTRODUCTION

Cryptococcus is a round or oval encapsulated yeast widely distributed in soil and pigeon droppings [1]. *Cryptococcus* is an opportunistic pathogen which mainly causes infections to immunocompromised hosts and less frequently to immunocompetent hosts [2]. Meningoencephalitis and pulmonary infections are frequently encountered manifestations of cryptococcosis [3], but disseminated infection can involve any other anatomic sites [4] such as skin, eyes, genitourinary tract, gastrointestinal tract and abdominal cavity. There are various kinds of cryptococcal infections reported such as meningoencephalitis [5], pneumonia [6], lymphadenitis [7], colonic infection [8], peritonitis [9], cutaneous lesions [10], osteomyelitis [11], myositis [12] and chorioenteritis [13]. However there has been no cryptococcuria reported yet, we are first reporting two cases of cryptococcuria in

Korea. Clinical microbiology laboratory should be prepared to detect *Cryptococcus* in urine.

CASE REPORT

Case 1

On January 3th, 2011, a 71-year-old woman with liver cirrhosis, hypertension and diabetes was admitted to a ward of internal medicine via emergency room due to dyspnea, cough, sputum, and rhinorrhea. Her blood pressure, pulse rate, respiratory rate and body temperature were 120/64 mmHg, 56/min, 30/min and 35.5°C, respectively. Initial laboratory investigations revealed white blood cell (WBC) 5,300/uL, hemoglobin (Hb) 8.5 g/dL, platelet 58,000/uL, aspartate aminotransferase/alanine aminotransferase (AST/ALT) 29/18 IU/L, alkaline phosphatase 178 IU/L, gamma-glutamyl transpeptidase 36 IU/L, total bilirubin 1.6 mg/dL, direct bilirubin 0.4 mg/dL, C-reactive protein (CRP) 0.81 mg/dL, blood urea nitrogen (BUN) 43 mg/dL, and creatinine 1.3 mg/dL. Urinalysis revealed trace of albumin, 3+ of Hb, and no WBC. Ascites and crackles and wheezing on the both lungs were found by physical examination.

Received 29 July, 2011, Revised 11 October, 2011

Accepted 18 October, 2011

Correspondence: Mi-Na Kim, Department of Laboratory Medicine, Asan Medical Center, 88 Olympic-ro 43-gil, Songpa-gu, Seoul 138-736, Korea. (Tel) 82-2-3010-4511, (Fax) 82-2-478-0884, (E-mail) mnkim@amc.seoul.kr

However paracentesis was failed, and it has been never tried again due to her representative's objection. High resolution computed tomography (CT) of the chest suggested either focal pneumonia with bilateral pleural effusions or asthma (Fig. 1). 30 mg of methylprednisolone a day has been administered intravenously under the impression of acute exacerbation of asthma since hospital day (HD) 3. Nasopharyngeal swab specimen was human rhinovirus-positive on reverse transcriptase PCR. Urine microscopy showed many yeasts but no WBC on HD 10. On HD 16, she became drowsy and oliguric. CT and magnetic resonance imaging of the brain showed no lesion but mild brain atrophy. CRP was 0.23 mg/dL and creatinine was 1.9 mg/dL. The cerebrospinal fluid (CSF) was colorless and clear with protein 14.9 mg/dL, glucose 112 mg/dL, red blood cell (RBC) 0/mm³, and WBC 1/mm³. It was negative for india ink preparation, calcofluor white stain-KOH mount and fluorochrome acid-fast bacilli (AFB) stain. CSF culture for bacteria, fungus and AFB were all negative. Quantitative urine culture was performed using sheep blood agar plate (BAP) and MacConkey agar plate, and pure colonies of a yeast over 100,000 CFU/mL were detected on BAP on HD 18. The yeast was germ

tube-negative (Fig. 2), but entirely round and budding without hyphae or pseudohyphae, which alarmed the examining technician suggesting *Cryptococcus*. It was urease-positive and positive with a latex agglutination test for cryptococcal antigen (PASTOREX Crypto Plus, Bio-Rad). Glucose assimilation testing using API 20C AUX (bioMérieux, France) identified the organism as *Cryptococcus neoformans* (bionumber 2116133) with probability of 98.5%. Antifungal susceptibility testing by ATB-FUNGUS III (bioMérieux, France) was all susceptible to 5-flucytosine, amphotericin B, and fluconazole. On HD 25, peripheral blood WBC was 24,900/uL, CRP was 5.63 mg/dL, and serum creatinine was 4.5 mg/dL, and hemodialysis was started. Urinalysis revealed 3+ of albumin, 3+ of Hb, WBC 11-20/HPF, RBC 21-30/HPF with many yeasts, and urine culture yielded *Candida albicans* over 100,000 CFU/mL. Cryptococcal antigen was positive with urine but negative with CSF and serum at that time. On HD 26 fluconazole started as 200 mg a day. Each 3 sets of blood cultures were performed on HD 26 and 27. *Acinetobacter baumannii* grew in one set of HD 26 and three sets of HD 27. The patient expired due to septic shock 3 days later.

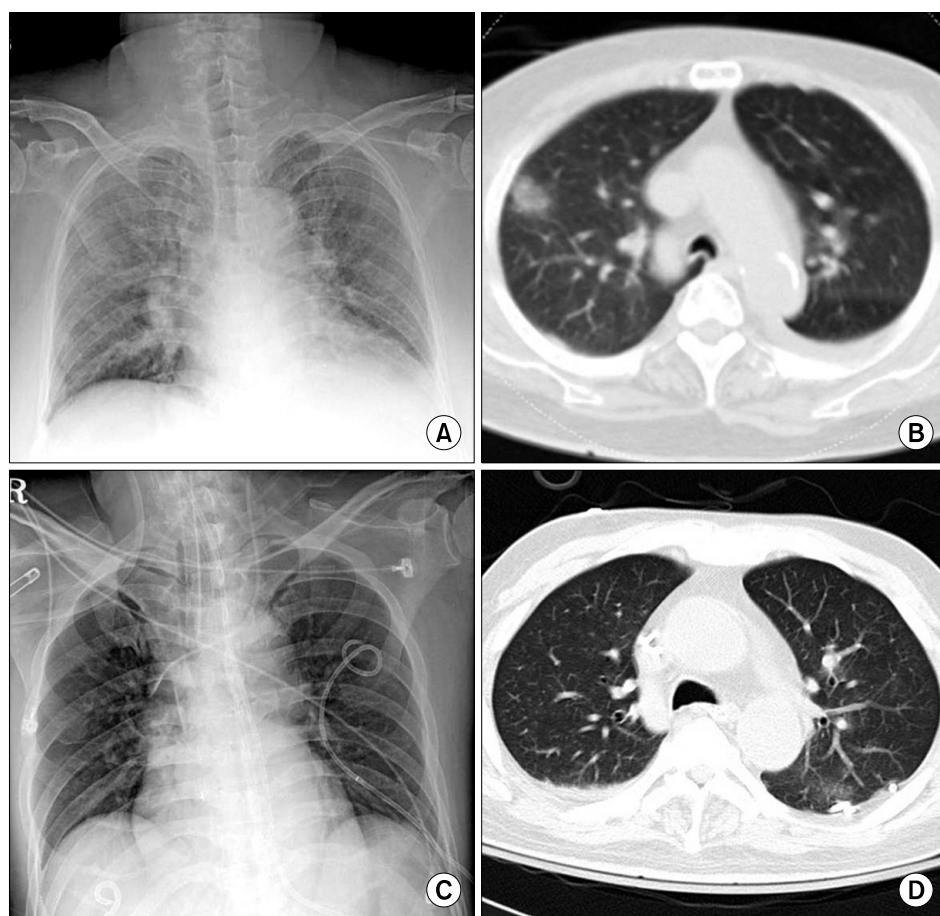


Fig. 1. Chest X-ray and CT of two patients. Patient 1 showed slightly increased patchy ground glass opacity in right upper lobe on chest X-ray (A) and areas of patch ground glass opacity in right upper lobe and diffuse bronchial wall thickening in both lungs on CT suggesting focal pneumonia (B). Patient 2 showed no active lung lesion on chest X-ray (C), but patchy faint ground glass opacities and small amount of right pleural effusion on CT at HD 25 (D).

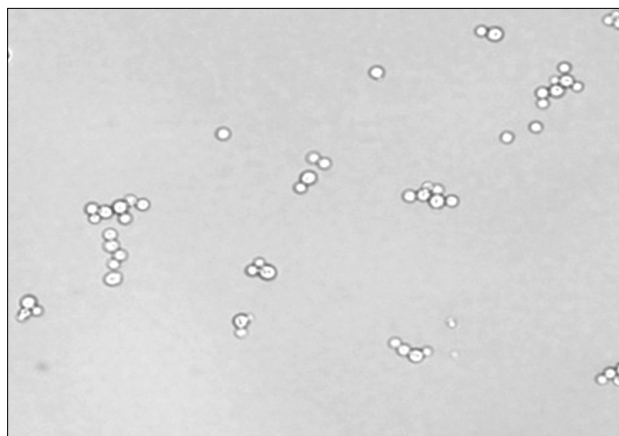


Fig. 2. Germ tube test of the isolates from the patient 1. 3–4 μ m spherical yeasts showed single budding connected with a narrow neck and negative germ tube reaction ($\times 400$).

Case 2

On 7th March 2011, a 50-year old male with HBV-associated hepatic failure was admitted to the medical intensive care unit via emergency room due to hepatic encephalopathy. Initial blood pressure, pulse rate, respiratory rate and body temperature were 120/80 mmHg, 121/min, 22/min and 36.2°C. Initial laboratory investigations revealed WBC 17,500/uL, Hb 12.2 g/dL, platelet 174,000/uL, AST/ALT 81/53 IU/L, total bilirubin 38.4 mg/dL, direct bilirubin 21.6 mg/dL, CRP 4.08 mg/dL, BUN 34 mg/dL, and creatinine 5.4 mg/dL. He presented reactivated HBV hepatitis, before transferred to the hospital. At presenting time, Anti-HBc IgM Ab and HBsAg were positive, but HBV DNA level was 6.1×10^2 IU/mL. Urinalysis showed trace of albumin, 1+ of nitrite, 1+ of WBC, 3+ of bilirubin and 4+ of Hb. On HD 13, He received cadaveric liver transplantation and started to take 40–80 mg methylprednisolone and 2 mg tacrolimus daily. Amphotericin B (50 mg a day) was administered as a prophylaxis. MRSA was isolated from abdominal drainage on HD 15, from a tip of central venous catheter on HD 17, and sputum on HD 18. Vancomycin 1,000 mg/day and meropenem 1,500 mg/day were administered on the same day. *C. neoformans* was cultured from sputum on HD 22. It was identified by API 20C AUX (2747031, 86.1%), and antifungal susceptibility testing revealed susceptibility to 5-flucytosine, amphotericin B, and fluconazole. Routine urine culture taken on HD 25 was positive for *C. neoformans*. At that time CSF and blood fungal cultures were negative. Serial follow-up of brain CT and abdomen CT showed no specific lesions, but chest CT scan demonstrated small ill-defined patchy opacities on both upper lung

fields with pleural effusion suggested atypical pneumonia (Fig. 1). Subsequently, dosage of amphotericin B was raised up to 150 mg a day. On HD 33, urine microscopy showed RBC 11–20/HPF, WBC 3–5/HPF with many yeast cells. He has been staying at the hospital over 2 months because hepatic function was not restored. No *C. neoformans* was recovered from sputum any more, but cryptococcuria lasted until now over 2 months.

DISCUSSION

Both cases had *C. neoformans* with urine cultures. Case 1 had isolated cryptococcuria and it was disappeared spontaneously. However it is unclear whether there was true resolution or not, because cryptococcal antigen test was kept to be positive. We were not able to do further investigation, since she expired soon after follow-up culture was done. Case 2 had a disseminated cryptococcosis involving at least the respiratory tract and the genitourinary tract. To our knowledge, these two cases represented the first report of cryptococcuria in Korea.

Case 2 was a recipient of the liver on immunosuppressive therapy. The medication was possible to make him immunocompromised to get disseminated cryptococcosis, however case 1 received prednisolone only for 14 days. There is a report that cryptococcal meningitis was developed after 12 days of prednisolone therapy in an autoimmune hemolytic anemia patient [14]. Therefore it is possible to impair immunity to cause disseminated cryptococcosis with short-term corticosteroid therapy. Additional underlying conditions such as diabetes [15] and liver cirrhosis [16] might contribute to her impaired immunity in case 1. Predisposing risk factors for disseminated cryptococcosis are known as AIDS, prolonged treatment with glucocorticoids, organ transplantation, malignancy, and sarcoidosis [2]. Patients with liver cirrhosis are susceptible to cryptococcal peritonitis [16]. Case 1, possibly might have cryptococcal peritonitis, however we failed to exam her ascitic specimen.

In AIDS patients, positive cryptococcal antigen detection from urine is strongly associated with disseminated mycosis [17]. Culture-proven cryptococcuria is relatively uncommon, and isolated cryptococcuria is more rarely reported on the literatures. In 16 patients with positive urine culture for *C. neoformans*, 81 percent of patients showed disseminated cryptococcosis simultaneously or latently [18]. There were three cases of isolated cryptococcuria [18], but none of them had any symptoms of urinary tract infection. Two patients had underlying conditions like HIV and chronic renal failure, respectively. The other patient was

young and apparently healthy, but lost to follow up. Case 1 became culture-negative for *C. neoformans* in urine after 10 days without any antifungal drugs, however, urine was still positive for cryptococcal antigen. It may be due to low sensitivity of cultures [19] or cryptococcal antigen could be detected as a form of degraded cell debris or soluble antigen liberated from primary infectious sites such as cryptococcal peritonitis [17]. In disseminated cryptococcosis, cryptococcal antigen can exist for a long time in CSF, blood, and urine despite of appropriate antifungal therapy [19]. Prolonged culture-proven cryptococcuria, however, is very rare condition. In our second case, he has been administered high dose of amphotericin B, but serial urine cultures still reveal cryptococcuria.

Renal involvements of *C. neoformans* were pathologically described previously [20]. However pathologic lesions of genitourinary tract has rarely been reported in patients having cryptococcuria [21]. Abdominal and pelvic CT of our cases did not show any pathologic lesions in the kidneys. *Cryptococcus* can spread to other anatomic sites by bloodstream and penetrate capillary wall as a mode of phagocytosis by macrophages or direct transcytosis [22]. Cryptococcuria can be occurred by shedding though glomeruli or seminal fluid in disseminated cryptococcosis, or can be true genitourinary infections.

Yeast isolates of urine cultures are not always identified to species level. In our laboratories only microscopy and germ tube test were routinely performed to rule out *Candida albicans* and *Trichosporon* species for yeast isolates from urine. Therefore *Cryptococcus* species could be missed from urine culture. Because cryptococcuria is a clue to diagnose for disseminated cryptococcosis, identification of *Cryptococcus* from urine isolates is valuable. Careful examination of morphology during germ tube tests would be an option to identify *Cryptococcus* as our cases, and technicians should keep the possibility of *Cryptococcus* in mind. Direct detection of cryptococcal antigen from urine may be desirable in high risk patients such as AIDS, organ transplant recipients or patients receiving prolonged corticosteroid therapy.

REFERENCES

- Currie BP, Freundlich LF, Casadevall A. Restriction fragment length polymorphism analysis of *Cryptococcus neoformans* isolates from environmental (pigeon excreta) and clinical sources in New York City. *J Clin Microbiol* 1994;32:1188-92.
- Idnurm A, Bahn YS, Nielsen K, Lin X, Fraser JA, Heitman J. Deciphering the model pathogenic fungus *Cryptococcus neoformans*. *Nat Rev Microbiol* 2005;3:753-64.
- Lin X. *Cryptococcus neoformans*: morphogenesis, infection, and evolution. *Infect Genet Evol* 2009;9:401-16.
- Mitchell TG and Perfect JR. Cryptococcosis in the era of AIDS—100 years after the discovery of *Cryptococcus neoformans*. *Clin Microbiol Rev* 1995;8:515-48.
- Lee SJ, Choi HK, Son J, Kim KH, Lee SH. Cryptococcal meningitis in patients with or without human immunodeficiency virus: experience in a tertiary hospital. *Yonsei Med J* 2011;52:482-7.
- Song KD, Lee KS, Chung MP, Kwon OJ, Kim TS, Yi CA, et al. Pulmonary cryptococcosis: imaging findings in 23 non-AIDS patients. *Korean J Radiol* 2010;11:407-16.
- Kim SH, Kim SD, Kim HR, Yoon CH, Lee SH, Kim HY, et al. Intraabdominal cryptococcal lymphadenitis in a patient with systemic lupus erythematosus. *J Korean Med Sci* 2005;20:1059-61.
- Song JC, Kim SK, Kim ES, Jung IS, Song YG, Yu JS, et al. A case of colonic cryptococcosis. *Korean J Gastroenterol* 2008;52:255-60.
- Park WB, Choe YJ, Lee KD, Lee CS, Kim HB, Kim NJ, et al. Spontaneous cryptococcal peritonitis in patients with liver cirrhosis. *Am J Med* 2006;119:169-71.
- Kang HY, Kim NS, Lee ES. Primary cutaneous cryptococcosis treated with fluconazole. *Korean J Dermatol* 2000;38:838-40.
- Oh R, Song EH, Park KH, Cho OH, Kim T, Yun GJ, et al. A case of cryptococcal osteomyelitis with paraspinal abscess. *Infect Chemother* 2008;40:284-7.
- Heo ST, Bae IG, Park JY, Kim SJ. Myositis due to *Cryptococcus neoformans* in a diabetic patient. *Korean J Clin Microbiol* 2009;12:141-3.
- Kim IT, Kim JY, Kim HG. A case of cryptococcal chorioretinitis in a renal transplant patient. *J Korean Ophthalmol Soc* 2002;43:922-6.
- Hong SI, Song MJ, Kim YS, Kim TH, Lee DG, Lee HK, et al. A case of cryptococcal meningitis developed after short-term therapy of steroid in a patient with autoimmune hemolytic anemia. *Korean J Hematol* 2004;39:191-5.
- Martos JA, Vendrell J, Abos J, Ribera G. Diabetes mellitus as a predisposing factor in cryptococcal meningitis. *An Med Interna* 1989;6:276-7.
- Mabee CL, Mabee SW, Kirkpatrick RB, Koletar SL. Cirrhosis: a risk factor for cryptococcal peritonitis. *Am J Gastroenterol* 1995;90:2042-5.
- Chapin-Robertson K, Bechtel C, Waycott S, Kontnick C, Edberg SC. Cryptococcal antigen detection from the urine of AIDS patients. *Diagn Microbiol Infect Dis* 1993;17:197-201.
- Kiertiburanakul S, Sungkanuparph S, Buabut B, Prachartam R. Cryptococcuria as a manifestation of disseminated cryptococcosis and isolated urinary tract infection. *Jpn J Infect Dis* 2004;57:203-5.
- Saha DC, Xess I, Biswas A, Bhowmik DM, Padma MV. Detection of *Cryptococcus* by conventional, serological and molecular methods. *J Med Microbiol* 2009;58:1098-105.
- Chung S, Park CW, Chung HW, Chang YS. Acute renal failure presenting as a granulomatous interstitial nephritis due to cryptococcal infection. *Kidney Int* 2009;76:453-8.
- Randall RE Jr, Stacy WK, Toone EC, Prout GR Jr, Madge GE, Shadomy HJ, et al. Cryptococcal pyelonephritis. *N Engl J Med* 1968;279:60-5.
- Kronstad JW, Attarian R, Cadieux B, Choi J, D'Souza CA, Griffiths EJ, et al. Expanding fungal pathogenesis: *cryptococcus* breaks out of the opportunistic box. *Nat Rev Microbiol* 2011;9:193-203.

=국문초록=

단독 크립토코쿠스 뇨증과 파종 크립토코쿠스증으로 발현한 크립토코쿠스 뇨증 2예울산대학교 의과대학 서울아산병원 ¹진단검사의학교실, ²감염내과학교실, ³외과학교실배미현¹, 남궁승¹, 안동희¹, 김미나¹, 김성한², 박기호², 이승규³

크립토코쿠스는 면역저하자에게 감염을 흔히 일으키는 기회 감염 진균이며 면역력 손상이 없는 환자에게도 감염을 일으킬 수 있다. 수막뇌염이나 호흡기 감염과 같은 전신적인 감염증은 높은 이환율, 사망률과 관계가 있다. 요로계의 크립토코쿠스 감염은 크립토코쿠스 전신 감염증이 있는 후천성 면역 결핍 증후군 환자들에게서 드물게 보고된다. 당뇨와 간경변이 있는 71세 여자와 B형 간염성 간부전으로 간이식을 받은 50세 남자에서 크립토코쿠스 뇨증을 경험하여 보고하고자 한다. 여자 환자는 요검체에서 크립토코쿠스가 배양되기 전 호흡기 증상이 있어 천식치료를 위해 12일간 프레드니솔론 투여를 받았다. 크립토코쿠스증에 대한 항진균제 치료를 하지 않았는데도 요배양은 음성으로 바뀌었으나, 크립토코쿠스 요항원은 입원 25일까지 양성이었다. 그녀의 뇌척수액 및 혈액 배양과 크립토코쿠스 항원 검사는 음성으로 단독 크립토코쿠스 뇨증으로 진단하였다. 남자 환자는 간이식 이후 프레드니솔론과 tacrolimus의 치료를 시작해서 10일째에 객담과 요에서 크립토코쿠스가 배양되었다. 당시에 시행된 흉부 전산화단층촬영에서 양쪽 폐에 경계가 불분명한 폐결절과 흉막 삼출이 관찰되었다. 이 환자는 이후 amphotericin B 치료를 받았으나 이후 2개월 이상 요에서 크립토코쿠스가 배양되어 파종 크립토코쿠스증으로 진단하였다. [대한임상미생물학회지 2011;14:148-152]

교신저자 : 김미나, 138-736, 서울시 송파구 올림픽로 43길 88번지
 울산대학교 의과대학 서울아산병원 진단검사의학과
 Tel: 02-3010-4511, Fax: 02-478-0884
 E-mail: mnkim@amc.seoul.kr