

## Spontaneous Bacterial Peritonitis with Septicemia with *Providencia rettgeri* and *Clostridium perfringens*

Sung Kuk Hong<sup>1</sup>, Sue Shin<sup>2,3</sup>, Jong-Hyun Yoon<sup>2,3</sup>, Eui-Chong Kim<sup>3</sup>

<sup>1</sup>Department of Laboratory Medicine and Research Institute of Bacterial Resistance, Yonsei University College of Medicine, <sup>2</sup>Department of Laboratory Medicine, Boramae Hospital, <sup>3</sup>Department of Laboratory Medicine, Seoul National University College of Medicine, Seoul, Korea

We report a suspicious case of spontaneous bacterial peritonitis (SBP) caused by *Providencia rettgeri* and *Clostridium perfringens* in a patient with alcoholic cirrhosis. The patient presented with altered mentality and was taken to the emergency room. He was diagnosed with SBP after abdominal paracentesis and computed tomography and was treated with ceftriaxone and metronidazole. The pathogens were identified under suspicion of polymicrobial infection because of Gram-staining discrepancies between broth from blood culture bot-

tles and colonies on solid media. He died of septic shock despite transfer to the intensive care unit. Although we could not conclude which organism had the leading role in this case of SBP and septicemia, we did verify the importance of Gram staining in a microbiology laboratory in terms of quality assurance. (**Ann Clin Microbiol 2014; 17:123-127**)

**Key Words:** *Clostridium perfringens*, *Providencia rettgeri*, Spontaneous bacterial peritonitis

### INTRODUCTION

Spontaneous bacterial peritonitis (SBP), first described in the mid-1960s, is defined as an infection of initially sterile ascitic fluid (AF) without a detectable, surgically treatable source of infection and is a frequent and severe complication of cirrhotic ascites [1,2]. SBP is diagnosed by polymorphonuclear leukocyte (PMN) counts  $>250$  cells/mm<sup>3</sup> in ascitic fluid [3]. The organisms responsible for SBP are isolated in 60-70% of cases [1], and are generally gut bacteria such as *Escherichia coli*, *Klebsiella pneumoniae*, and *Enterococcus faecalis* [2]. To the best of our knowledge, there are no reports of SBP caused by *Providencia rettgeri* and few reports of SBP caused by *Clostridium perfringens* [4]. Here we report a suspicious case of SBP with sepsis caused by both *P. rettgeri* and *C. perfringens*.

### CASE REPORT

A 47-year-old man was transported to the hospital by ambu-

lance and was taken to the emergency room because of altered mentality on June 5, 2013. The patient was a homeless man with no previous history of invasive abdominal procedures, who had been diagnosed with alcoholic liver cirrhosis in March 2010; after diagnosis, he had been examined at the gastrointestinal internal medicine outpatient clinic.

On admission to the emergency room, the patient had a temperature of 36.7°C, a blood pressure of 62/43 mmHg, a pulse of 140 beats/min, a respiratory rate of 40 breaths/min, and a Glasgow Coma Scale score of 11. Physical examination of the patient revealed no head injury and typical characteristics of chronic liver disease, including tense ascites, caput medusa, hepatomegaly, splenomegaly, and pedal edema.

His laboratory results were systemic inflammation [C-reactive protein (CRP) 4.32 mg/dL, normal  $<0.5$  mg/dL; blood leukocyte count  $3.7 \times 10^9$ /L with left shift] and impaired liver and kidney function [bilirubin 2.5 mg/dL, normal  $<1.2$  mg/dL; international normalized ratio (INR) 1.48; albumin 2.9 g/dL, normal  $>3.5$  g/dL; creatinine 4.21 mg/dL, normal  $<1.4$  mg/dL]. A cra-

Received 1 March, 2014, Revised 1 September, 2014, Accepted 2 September, 2014

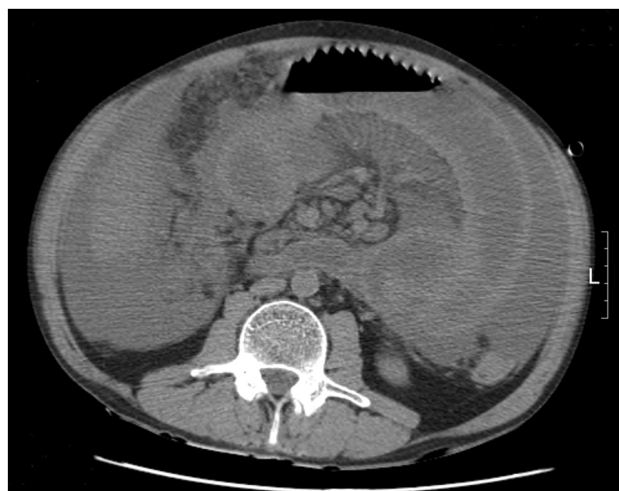Correspondence: Sue Shin, Department of Laboratory Medicine, Seoul National University Boramae Hospital, 20, Boramae-ro 5-gil, Dongjak-gu, Seoul 156-707, Korea. (Tel) 82-2-870-2602, (Fax) 82-2-870-2620, (E-mail) jeannie@snu.ac.kr

© The Korean Society of Clinical Microbiology.

© This is an Open Access article distributed under the terms of the Creative Commons Attribution Non-Commercial License (<http://creativecommons.org/licenses/by-nc/3.0>) which permits unrestricted non-commercial use, distribution, and reproduction in any medium, provided the original work is properly cited.

nial computed tomography (CT) scan to determine the cause of the patient's altered mentality revealed no evidence of hemorrhage. Diagnostic paracentesis revealed increased leukocyte and PMN counts of  $>1,000/\mu\text{L}$  and 52% of total leukocytes, total protein level of 3.4 g/dL, glucose level of 23 mg/dL, and lactate dehydrogenase level of 340 U/mL. Although the most probable diagnosis was secondary bacterial peritonitis based on AF analysis, there was no evidence of gastrointestinal tract perforation or abscess in abdominal CT images (Fig. 1). Based on the medical history and the CT findings, he was diagnosed with SBP and empirically prescribed ceftriaxone and metronidazole.

Before empirical antibiotic therapy, two sets of blood samples were collected and cultured in a BacT/Alert 3D system (bioMérieux, Marcy l'Etoile, France). An AF sample collected from paracentesis was inoculated onto both a blood agar plate (BAP) and a MacConkey agar plate (MAC) and incubated for 24 hr at 35°C in a 5% CO<sub>2</sub> atmosphere. White and mucous colonies were observed on BAP and MAC in the AF culture and the isolate was identified as *P. rettgeri* by the Vitek 2 system (bioMérieux). All blood culture bottles were "positive," and Gram staining revealed polymicrobial growth of gram-positive and gram-negative rods (Fig. 2A, B). The broth of positive blood cultures was inoculated onto BAPs and MACs and incubated for 24 hr at 35°C in a 5% CO<sub>2</sub> atmosphere, but only gram-negative rods with white and mucoid colonies were observed (Fig 2C, D). Suspecting a polymicrobial bacteremia with obligate anaerobe, the broth from the anaerobic bottle was subcultured onto a Brucella agar plate and cultured anaerobically.



**Fig. 1.** Noncontrast abdominal computed tomography image showing ascites, hepatomegaly and diffuse wall thickening of the small bowels.

After two days of incubation, gram-positive rods with beta-hemolytic colonies were observed (Fig. 2E, F). The gram-negative rods were identified as *P. rettgeri* with 99% probability and the gram-positive rods as *C. perfringens* with 99% probability by the Vitek 2 system (bioMérieux).

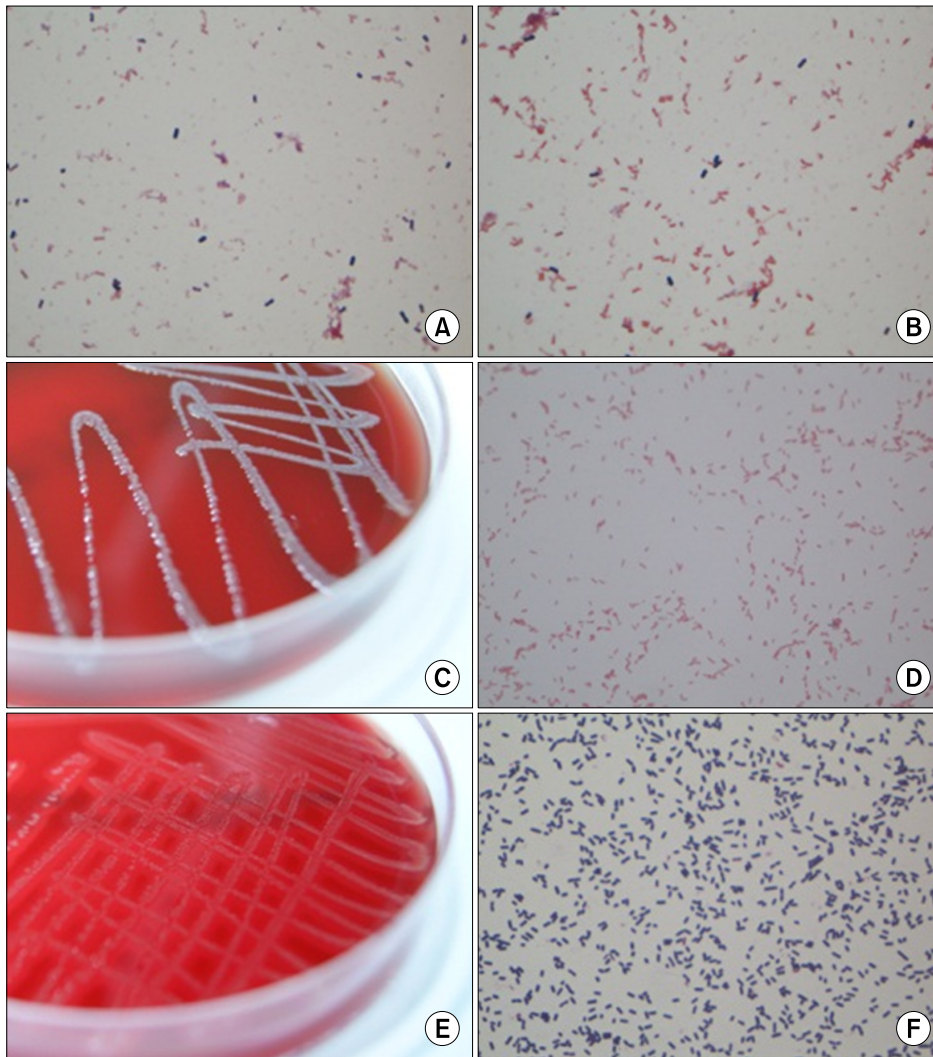
The antimicrobial susceptibility test (AST) performed using a Vitek 2 system (bioMérieux) showed that *P. rettgeri* was susceptible to all tested antibiotics: amikacin, aztreonam, cefuroxime, cefotaxime, cefotetan, ceftazidime, ciprofloxacin, gentamicin, imipenem, and trimethoprim/sulfamethoxazole, but AST for *C. perfringens*, obligate anaerobic bacilli, was not conducted. Although the AF was not cultured anaerobically, the patient was diagnosed with SBP with sepsis caused by *P. rettgeri* and *C. perfringens* based on the results of blood cultures. The patient was maintained on the original antibiotics while in the intensive care unit, but he died due to septic shock before the causative organisms were identified.

## DISCUSSION

SBP is a serious complication in cirrhotic patients with ascites [3]. Without early antibiotic treatment, this complication is associated with a 30-50% mortality rate [5]. Though SBP is diagnosed by increased PMN in ascites ( $>250$  cells/mm<sup>3</sup>) [3], rapid and accurate pathogen detection is important to improve the survival rate of patients with SBP [6].

*P. rettgeri* is a gram-negative, facultative anaerobic bacillus member of the family Enterobacteriaceae. It is one of the pathogenic causes of urinary tract infections. Less common infectious syndromes caused by *P. rettgeri* include intravascular device infections, ocular infections, renal infections, and bloodstream infections [7-9]. Bacteremia induced by *P. rettgeri* is rare; although Kim et al. reviewed 132 bacteremia cases caused by the tribe *Proteeae*, only three cases of *P. rettgeri* bacteremia were identified [8]. Peritonitis caused by *Providencia spp.* is very rare that only three cases were identified through literature review: dialysis-associated peritonitis by *P. stuartii*, dialysis-associated peritonitis by *P. rettgeri*, bacteremia that was ascitic PMN count  $<250$  cells/mm<sup>3</sup> and positive ascitic culture by *Providencia sp.*, which was not confirmed at species level [6, 10,11].

*C. perfringens* are gram-positive, spore-forming, obligate anaerobic bacilli that exhibit various clinical symptoms, including infections of skin and soft tissue, gas gangrene, necrotizing enteritis, liver abscesses, bacteremia, and septic shock [12].



**Fig. 2.** (A) Gram-positive and gram-negative rods from smear preparations of the positive aerobic blood culture bottle (Gram stain,  $\times 1,000$ ). (B) Gram-positive and gram-negative rods from smear preparations of the positive anaerobic blood culture bottle (Gram stain,  $\times 1,000$ ). (C) White and mucous colonies of *Providencia rettgeri* incubated for 24 hr at 35°C in a 5% CO<sub>2</sub> atmosphere on a blood agar plate. (D) Gram stain of *P. rettgeri* from smear preparations of the blood agar plate ( $\times 1,000$ ). (E) Flat colonies with beta-hemolysis of *C. perfringens* incubated for 48 hr anaerobically on a Brucella agar plate. (F) Gram stain of *Clostridium perfringens* from smear preparations of the Brucella agar plate ( $\times 1,000$ ).

More than half of patients with *C. perfringens* bacteremia have polymicrobial infections, and the 30-day mortality rate of patients with this bacteremia is as high as 27-44% [12]. Few cases of SBP caused by *C. perfringens* have been reported and SBP caused by anaerobic bacteria including *C. perfringens* has similar clinical presentation and risk factors compared with infection by common pathogens [4,13].

The patient has septicemia with *C. perfringens* and *P. rettgeri*. To identify polymicrobial bacteremia, we experienced the importance of Gram stains from blood culture-positive bottles. The discrepancy of Gram stains between broth of blood culture bottles and colonies on solid media allowed us to accurately identify the pathogens infecting this patient. We assume that the bacterial origin was intestinal owing to gut colonization. Although it is unclear which microorganism has the role of pri-

mary pathogen, the mortality might have been caused by *C. perfringens*, which has a high reported mortality rate [12]. SBP caused by *C. perfringens* or *P. rettgeri* is very rare, possibly owing to the relatively high oxygen concentration in AF, which makes survival of anaerobic bacteria difficult [14,15]. Because this patient had alcoholic liver cirrhosis, he may have had immune and nutritional deficiencies, and complement deficiency, which increase susceptibility to bacterial infection. Patients with SBP should seek and receive prompt medical treatment because they are immunosuppressed. The patient was accurately diagnosed and appropriately treated but he died due to poor general condition and delayed hospital transfer.

In this case, the patient was SBP with septicemia with *P. rettgeri* and *C. perfringens*. This case report shows that *P. rettgeri* might be one of the potential pathogens of SBP combined with

*C. perfringens* in patients with underlying illnesses. Through this case, the importance of Gram stain is revisited in identifying polymicrobial infection in terms of the quality assurance in a microbiology laboratory.

## REFERENCES

1. Conn HO. Spontaneous peritonitis and bacteremia in Laennec's cirrhosis caused by enteric organisms. A relatively common but rarely recognized syndrome. *Ann Intern Med* 1964;60:568-80.
2. Dore MP, Casu M, Realdi G, Piana A, Mura I. *Helicobacter* infection and spontaneous bacterial peritonitis. *J Clin Microbiol* 2002;40:1121.
3. Lata J, Stiburek O, Kopacova M. Spontaneous bacterial peritonitis: a severe complication of liver cirrhosis. *World J Gastroenterol* 2009;15:5505-10.
4. Young PE, Dobhan RR, Schafer TW. *Clostridium perfringens* spontaneous bacterial peritonitis: report of a case and implications for management. *Dig Dis Sci* 2005;50:1124-6.
5. Garcia-Tsao G. Current management of the complications of cirrhosis and portal hypertension: variceal hemorrhage, ascites, and spontaneous bacterial peritonitis. *Gastroenterology* 2001;120:726-48.
6. Sugihara T, Koda M, Maeda Y, Matono T, Nagahara T, Mandai M, et al. Rapid identification of bacterial species with bacterial DNA microarray in cirrhotic patients with spontaneous bacterial peritonitis. *Intern Med* 2009;48:3-10.
7. Koreishi AF, Schechter BA, Karp CL. Ocular infections caused by *Providencia rettgeri*. *Ophthalmology* 2006;113:1463-6.
8. Kim BN, Kim NJ, Kim MN, Kim YS, Woo JH, Ryu J. Bacteraemia due to tribe Proteaeae: a review of 132 cases during a decade (1991-2000). *Scand J Infect Dis* 2003;35:98-103.
9. Lee G and Hong JH. Xanthogranulomatous pyelonephritis with nephrocutaneous fistula due to *Providencia rettgeri* infection. *J Med Microbiol* 2011;60:1050-2.
10. Unverdi S, Akay H, Ceri M, Inal S, Altay M, Demiroz AP, et al. Peritonitis due to *Providencia stuartii*. *Perit Dial Int* 2011;31:216-7.
11. Gloor HJ. 20 years of peritoneal dialysis in a mid-sized Swiss hospital. *Swiss Med Wkly* 2003;133:619-24.
12. Yang CC, Hsu PC, Chang HJ, Cheng CW, Lee MH. Clinical significance and outcomes of *Clostridium perfringens* bacteremia--a 10-year experience at a tertiary care hospital. *Int J Infect Dis* 2013;17:e955-60.
13. Targan SR, Chow AW, Guze LB. Role of anaerobic bacteria in spontaneous peritonitis of cirrhosis: report of two cases and review of the literature. *Am J Med* 1977;62:397-403.
14. Conn HO and Fessel JM. Spontaneous bacterial peritonitis in cirrhosis: variations on a theme. *Medicine (Baltimore)* 1971;50:161-97.
15. Sheckman P, Onderdonk AB, Bartlett JG. Anaerobes in spontaneous peritonitis. *Lancet* 1977;2:1223.

=국문초록=

## *Providencia rettgeri*와 *Clostridium perfringens*에 의한 원발성 복막염 및 패혈증 1예

<sup>1</sup>연세대학교 의과대학 진단검사의학교실, 세균내성연구소, <sup>2</sup>서울대학교 보라매병원 진단검사의학과,  
<sup>3</sup>서울대학교 의과대학 검사의학교실

홍성극<sup>1</sup>, 신수<sup>2,3</sup>, 윤종현<sup>2,3</sup>, 김의종<sup>3</sup>

저자들은 알코올성간경변 환자에서 *Providencia rettgeri*와 *Clostridium perfringens*에 의한 원발성 복막염 및 패혈증이 의심되는 1예를 경험하였다. 환자는 의식변화를 주소로 응급실 내원하여 복부천자와 복부전산화단층촬영을 통해 원발성 복막염으로 진단받고, 세프트리악손과 메트로니다졸로 치료를 받았다. 양성 혈액배양 배지와 고체 배지에서 증균한 균의 그람염색 결과의 차이로 인해 복합균을 검출할 수 있었다. 환자는 중환자실에서 치료를 받았지만 패혈쇼크로 사망하였다. 본 증례에서는 *P. rettgeri*와 *C. perfringens*중 어떤 것이 환자 질병의 주 원인균인지 확인할 수는 없었지만, 미생물검사실에서 정도관리측면에서 그람염색의 중요성을 재확인 할 수 있었기에 보고하는 바이다. [Ann Clin Microbiol 2014;17: 123-127]

교신저자 : 신수, 156-707, 서울시 동작구 보라매로5길 20  
서울대학교 보라매병원 진단검사의학과  
Tel: 02-870-2602, Fax: 02-870-2620  
E-mail: jeannie@snu.ac.kr